

# A Double-blind, Randomized Study Assessing a Hypochlorous Acid- (HOCl) Based Silicone Gel for Treating Hypertrophic and Keloid Scars

Mark Steven Nestor, MD, PhD and Brian Berman, MD, PhD; Center for Clinical and Cosmetic Research, Aventura, FL

### BACKGROUND

Scars are a common consequence of trauma, burns and surgery and occasionally may become hypertrophic. Scar management depends on individual patient risk of developing hypertrophic scars and concern for scar appearance and location.

Silicone-based products are currently recommended as the first-line option for preventing and treating excessive scarring after surgery or trauma. Hypochlorous acid (HOCl) appears to be effective, safe, and well tolerated for treating and preventing scars. Combining these agents may improve their effectiveness.

The combination of HOCl and silicone appears to affect the three phases of healing at the cellular level. HOCl reduces inflammation by decreasing mast cell degranulation and phospholipase A2 activity and increases cell proliferation through regranulation while silicone facilitates tissue remodeling via cell movement and attachment.

The objective of this 16-week double-blind, randomized study was to compare the efficacy of HOCl plus silicone (Microcyn® Technology) vs. silicone gel as a single agent (Kelo-Cote® Scar Repair Gel) for managing hypertrophic and keloid scars.

### METHODS

#### Participants

Adult subjects with linear or widespread hypertrophic or keloid scars were enrolled (N=40) and randomized 1:1 to treatment with HOCl plus silicone gel or silicone gel.

#### Procedures

Subjects were instructed to apply the investigational product three times daily, approximately every 8 hours, for 8 weeks. Each subjects was evaluated on Days 14, 28, 56, 84 and 112.

Scars were evaluated using the validated Vancouver Scar Scale (VSS).<sup>3</sup> The Investigator and each subject completed the VSS and symptom evaluations at each study visit. Overall efficacy was assessed with the Investigator Global Assessment (IGA) on Day 56 (end of treatment) and Day 112.

### RESULTS

Use of HOCl plus silicone and silicone gel each improved hypertrophic scar parameters including vascularity, pliability, height, pain and itch. The mean VSS among subjects treated with HOCl plus silicone gel decreased from 6.2 at Baseline to 3.5 at Day 112 while the mean VSS among subjects treated with silicone gel decreased from 5.78 and Baseline to 3.94 at Day 112 (Figure 1).

The mean VSS among subjects decreased by 43.5% and 31.8% among subjects treated with the HOCl plus silicone and silicone gel, respectively (Figure 2). The IGA scores for HOCl plus silicone gel were superior to silicone gel (Figure 3). An example of a hypertrophic scar treated with HOCl plus silicone gel is shown in Figure 4.

Figure 1. Changes in Vancouver Scar Scores

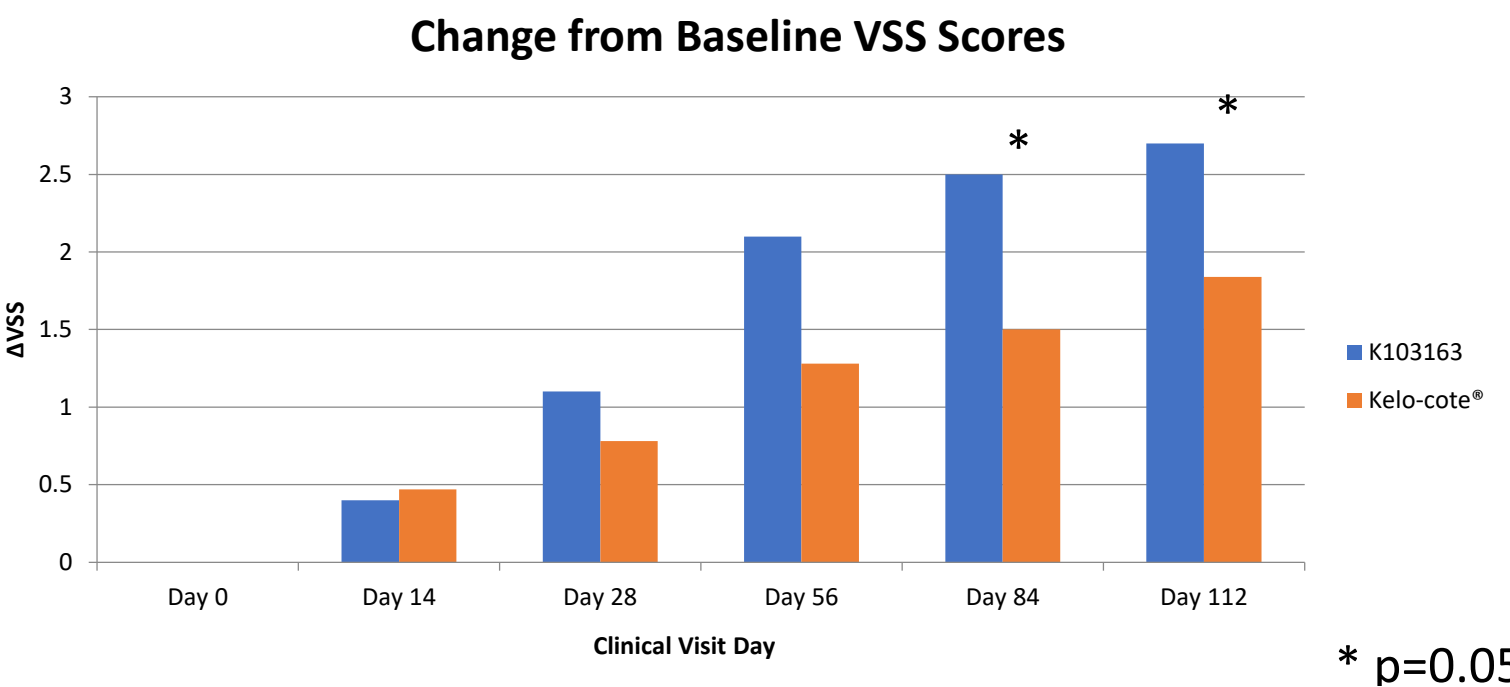


Figure 2. Percent Changes in Vancouver Scar Scores

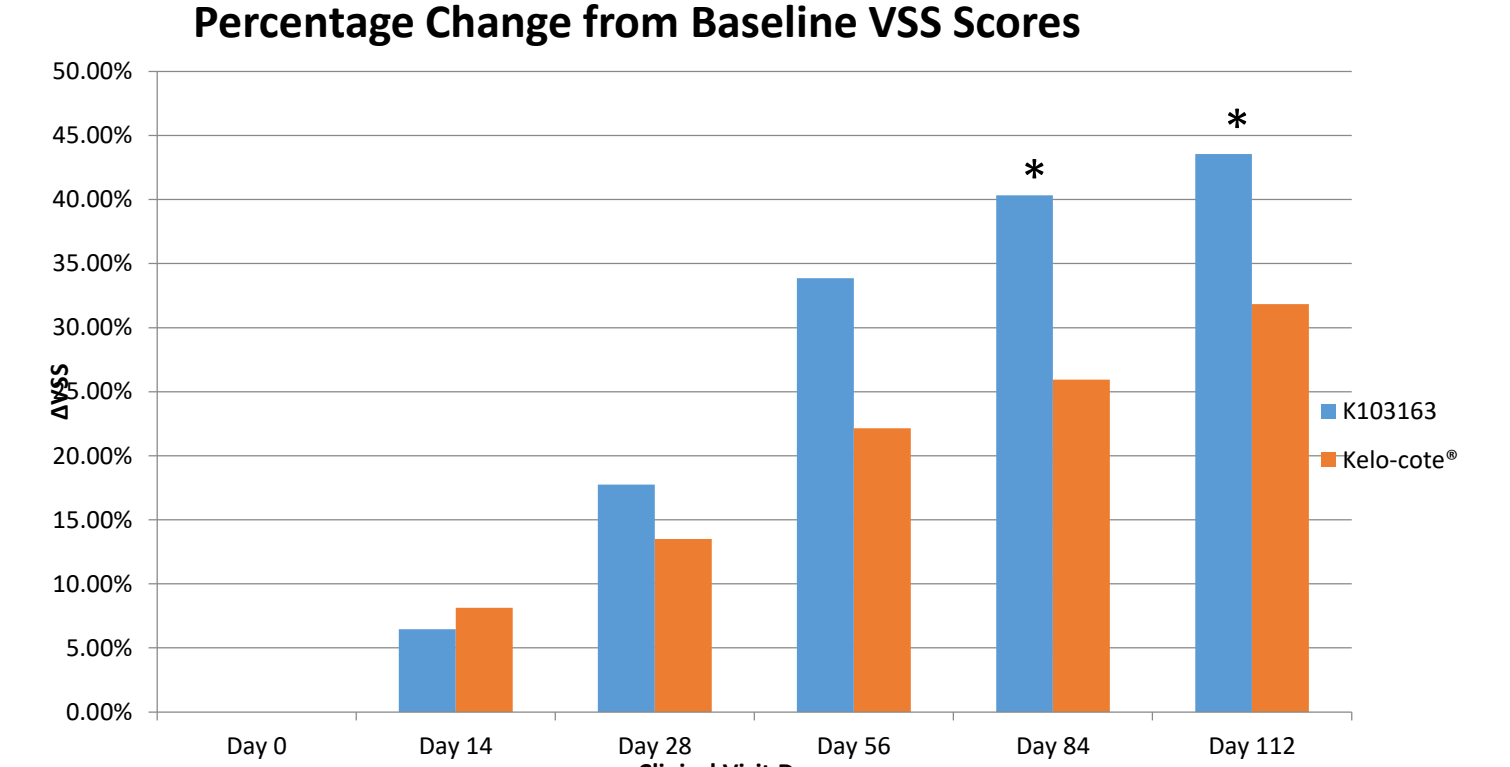


Figure 3. Changes in Investigator Global Assessment

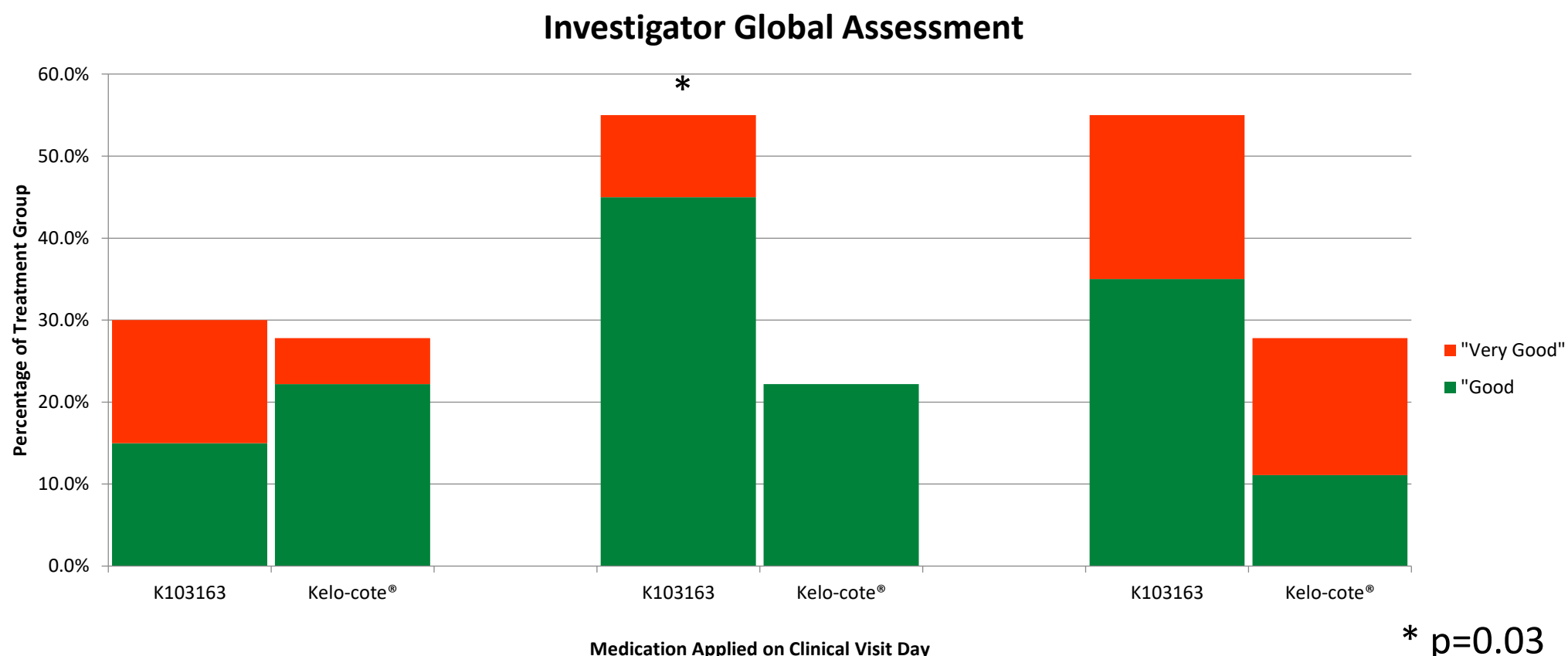
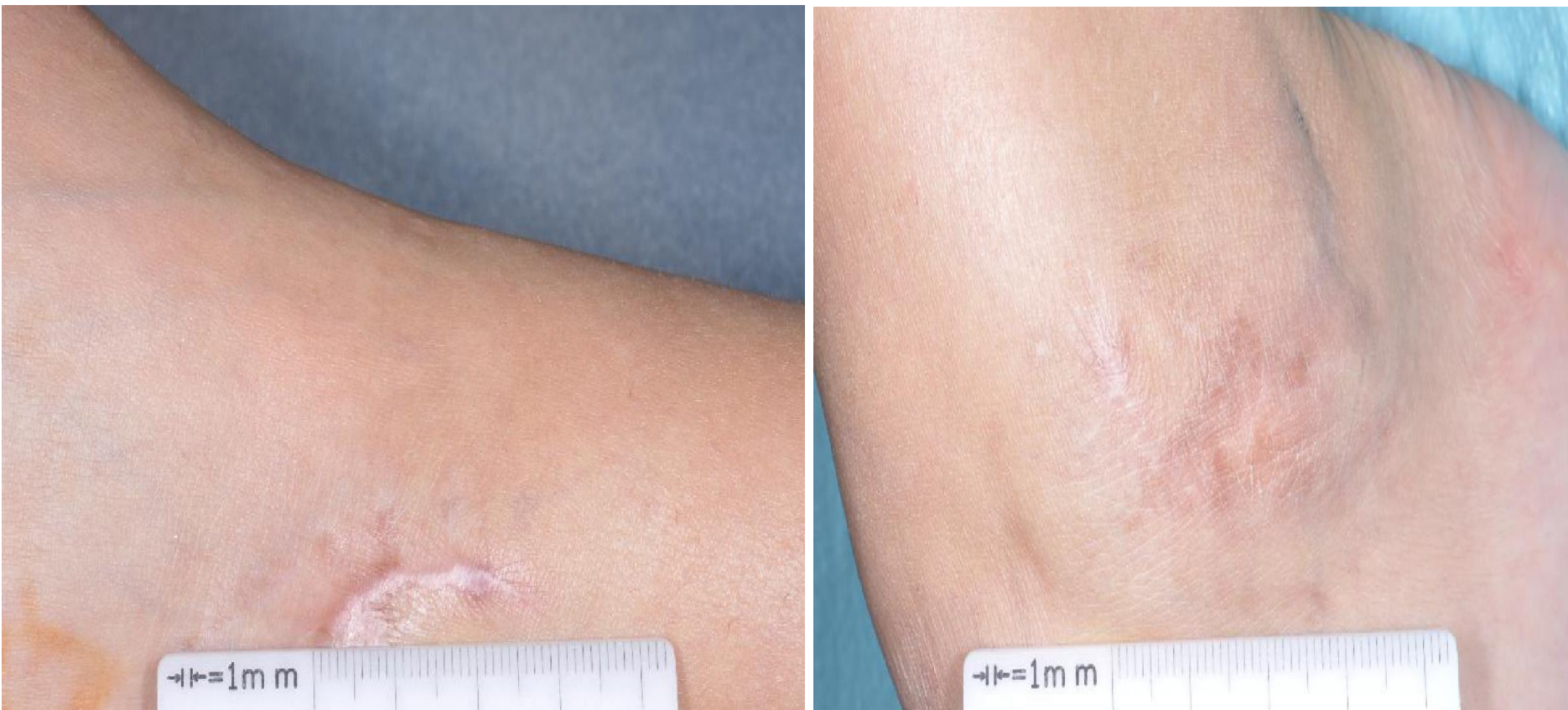

Figure 4. A 6-Month Old Linear Hypertrophic Surgical Scar at Baseline (left) and 16 Weeks After Treatment with HOCl plus Silicone Gel (right)



### CONCLUSION

HOCl plus silicone gel is effective for treating hypertrophic scars and demonstrated superiority over silicone gel as a single agent. No significant product-related adverse events occurred in either treatment group

### ACKNOWLEDGEMENT

This study was sponsored by IntraDerm Pharmaceuticals, Jamison, PA

### REFERENCES

1. Meaume S, Le Pillouer-Prost A, Richert B, et al. Management of scars: updated practical guidelines and use of silicones. *Eur J Dermatol.* 2014;24:435-43.
2. Gold MH, Andriessen A, Dayan SH, et al. Hypochlorous acid gel technology - its impact on post-procedure treatment and scar prevention. *J Cosmet Dermatol.* 2017;16:162-167.
3. Baryza MJ, Baryza GA. The Vancouver Scar Scale: an administration tool and its interrater reliability. *J Burn Care Rehabil.* 1995;16:535-8.